



MOUNT SINAI
SCHOOL OF
MEDICINE

Detection and Management of Skull base Cerebrospinal fluid leaks using HRCT-MRI Fusion Imaging

Abib Agbetoba, MD¹; Satish Govindaraj, MD¹; Bradley Delman, MD¹; Joshua Bederson, MD¹
¹Mount Sinai School of Medicine

ABSTRACT

Abstract

Background:

Endoscopic repair of cerebrospinal fluid (CSF) leaks has been well described in the literature as an effective method for the treatment of sinonasal skull base defects. [1] However despite the ongoing evolution of endoscopic techniques for repair, site localization remains a diagnostic challenge.

Methods:

We retrospectively reviewed 16 cases of patients who underwent HRCT-MRI fusion studies with intraoperative fluorescein localization for the evaluation and repair of CSF leaks during a three year period between 2008 and 2011 at the Mount Sinai Medical Center.

Results:

24 HRCT-MRI fusion studies were evaluated from patients suspected of having anterior skull base CSF leaks. 19 of 24 subjects had a confirmed diagnosis of CSF leak on intra-operative nasal endoscopy and/or B2 transferrin. HRCT-MRI fusion imaging accurately identified the CSF leak and its location in each of the 19 subjects yielding a sensitivity of 100%. 4 of the 24 patients were found to have no signs of active leak or skull base defect on intra-operative nasal endoscopy, 3 of which correlated with negative findings on fusion imaging. One additional patient found to have a negative HRCT-MRI fusion study underwent two CT cisternography, each negative and confirming the absence of a CSF leak.

Conclusion:

HRCT-MRI fusion is an excellent imaging modality that not only provides accurate identification and localization of CSF leaks but also acts as a great adjunct for intra-operative localization and repair. HRCT-MRI fusion imaging should be incorporated into the diagnostic algorithm for the management of CSF leaks.

CONTACT

Abib Agbetoba, MD & Satish Govindaraj, MD
Mount Sinai School of Medicine
Abib.agbetoba@mssm.edu
Satish.govindaraj@mssm.edu
Phone: 212-241-9410

INTRODUCTION

Surgical endoscopic approach to the anterior skull base has been well documented in literature as an effective and conventional means for the treatment of cerebral spinal fluid (CSF) leaks with reported success rate of over 90%. [1] Continued advancements in endoscopic equipment and technique have improved surgical outcomes by providing greater exposure and higher resolution imaging through a minimally invasive approach. However despite the ongoing evolution of endoscopic surgery and neuroradiographic imaging there continues to be limitations, particularly with site localization in patients with CSF leaks.

METHODS & TECHNIQUE

A retrospective chart review was conducted on all patients who underwent HRCT-MRI fusion imaging for the evaluation of CSF leak presenting between 2008 and 2011.

Initial diagnosis or clinical suspicion of CSF leakage was made based on either subject's history of persistent clear nasal discharge, nasal endoscopy significant for CSF rhinorrhea, or laboratory confirmation of CSF through beta-2-transferrin analysis.

16 subjects with presumed CSF leakage were then referred to obtain HRCT and MRI imaging to be performed consecutively on the same day. CT imaging included a non-contrast helical acquisition with reconstructed images of the paranasal sinuses and temporal bones. Images were reconstructed with a 35% overlap (0.625mm images every 0.4mm) to minimize step-ladder artifact during processing. MR imaging was then performed using combined sinus and temporal bone clinical protocol, both pre and post IV gadolinium. Acquisition included a volumetric T2 CUBE (extended echo train T2 volumetric acquisition) in the coronal plane to optimize characterization of fluid. Source CT data and MR T2 CUBE images were sent to a dedicated post-processing workstation capable of independently co-registering data sets. To achieve registration, field of view was matched between the sets, and then translation and rotation were progressively modified until the datasets were in alignment. Fused images are portrayed with the T2 sequences indicated in a color gradient (rainbow spectrum) superimposed over grayscale bone images.

Patients obtaining HRCT-MRI fusion imaging subsequently underwent intraoperative fluorescein localization for the evaluation and repair of CSF leaks.

HRCT-MRI Fusion Imaging

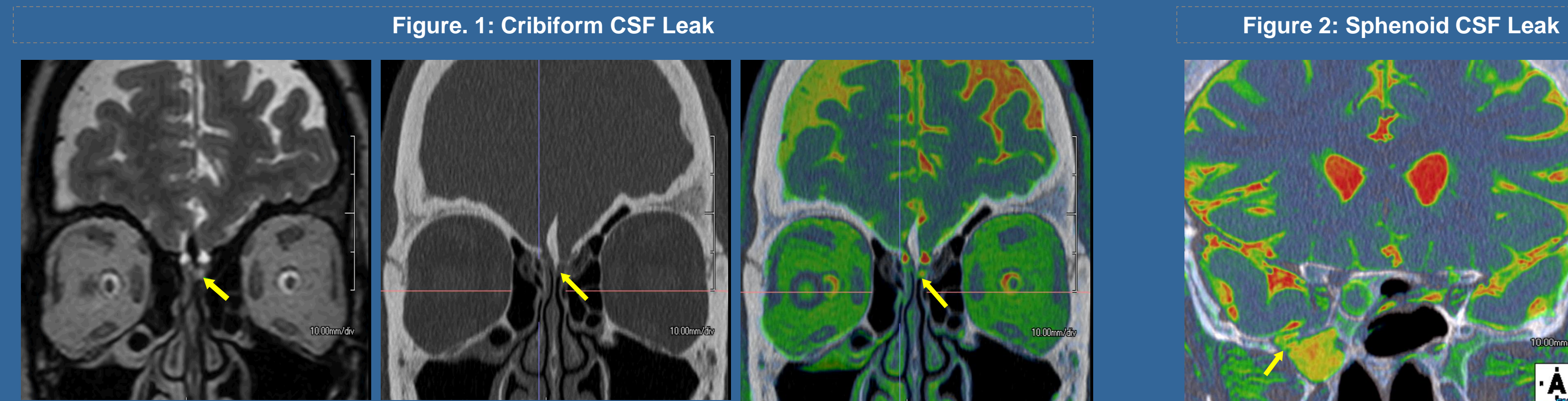


Figure 1. Cribiform CSF leak. Coronal T2 image (A) reveals asymmetric high signal in the left olfactory recess (arrow), which is not present on the right. CT (B) demonstrates intermediate density corresponding to this fluid. The olfactory groove is also wider on this side. Fused CT-MR image (C, with CT in grayscale and T2 in color) clearly shows site of fluid (arrow) relative to bony landmarks.

Figure 2. Sphenoid CSF leak. Coronal fused CT-MR image (with CT in grayscale and T2 in color) clearly shows site of CSF communication (arrow) with the lateral right sphenoid sinus through an osseous defect.

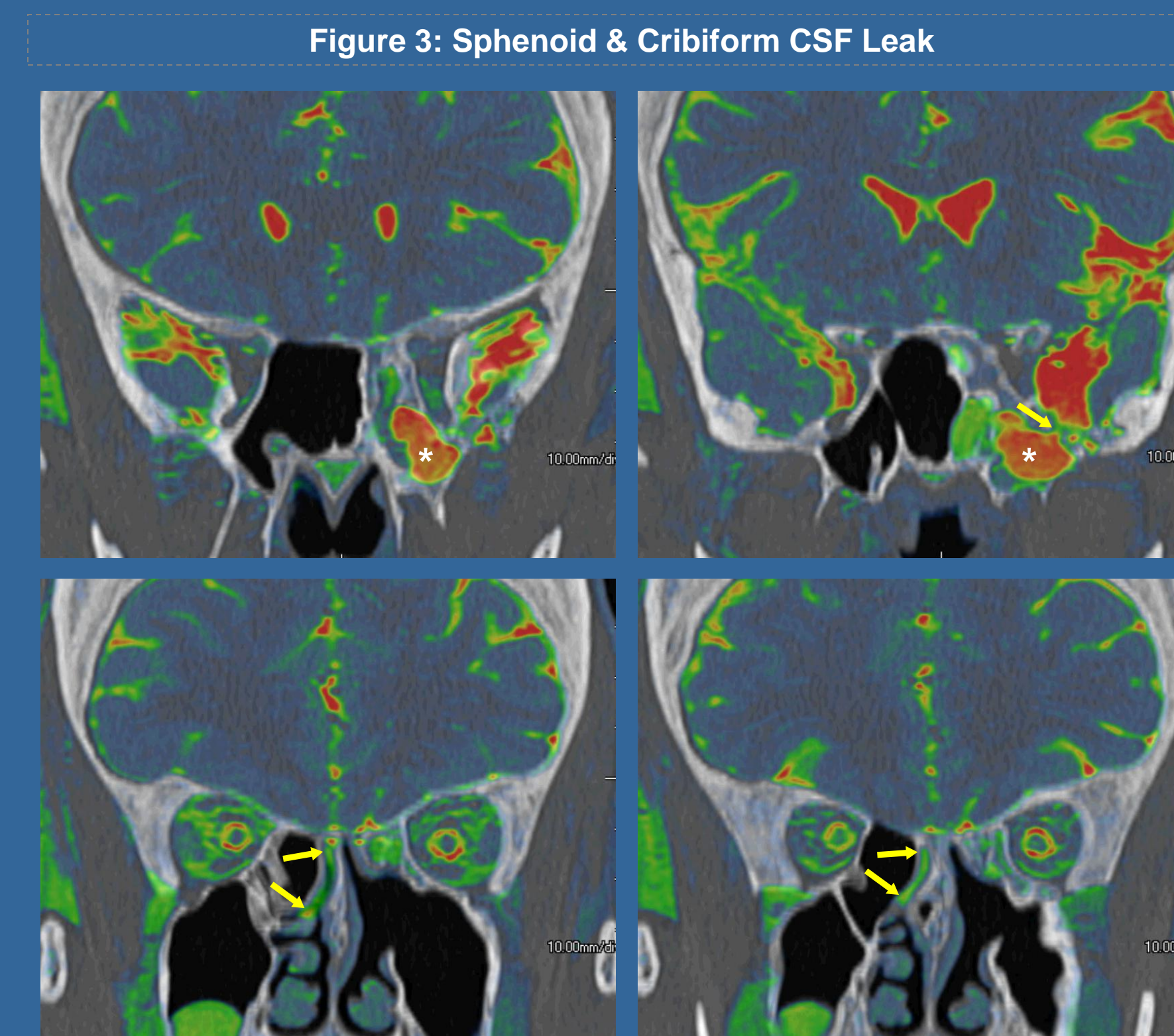


Figure 3. Coronal fused CT-MR images in a patient with multiple prior sinus procedures including prior CSF leak repair. Fluid pools in the left sphenoid sinus (asterisk in A&B) from site of previous leakage (arrow in B). Patient developed a new site of CSF leakage through the right cribiform region with fluid projecting inferiorly from the right olfactory recess (arrows in C & D).

RESULTS

	(+) CSF Leak	(-) CSF Leak	
(+) HRCT-MRI	19	1	PPV = 95%
(-) HRCT-MRI	0	4	NPV = 100%
	Sensitivity = 100%	Specificity = 80%	
	95% CI (.79-1.0)	95% CI (.30 -.99)	

REFERENCES

- Woodworth B.A. and J.N. Palmer. Spontaneous cerebrospinal fluid leaks. Current opinion in otolaryngology & head and neck surgery. 2009. 17(1): p. 59-65.
- Wise, S.K. and R.J. Schlosser. Evaluation of spontaneous nasal cerebrospinal fluid leaks. Current opinion in otolaryngology & head and neck surgery. 2007. 15(1): p. 28-34.
- Presutti, L. et al. Transnasal endoscopic treatment of cerebrospinal fluid leak: 17 years' experience. Acta otorinolaryngologica Italica : organo ufficiale della Societa italiana di otorinolaryngologia e chirurgia cervico-facciale. 2009. 29(4): p. 191-6.
- Hofmann, E., R. Behn, and K. Schwager. Imaging of cerebrospinal fluid leaks. Klinische Neuroradiologie. 2009. 19(2): p. 111-21.
- Payne, R.J., et al. Role of computed tomographic cisternography in the management of cerebrospinal fluid rhinorrhea. The Journal of otolaryngology. 2003. 32(2): p. 93-100.
- Friedman, J.A., M.J. Ebersold, and L.M. Quast. Post-traumatic cerebrospinal fluid leakage. World journal of surgery. 2001. 25(8): p. 1062-6.
- Rice, D.H. Cerebrospinal fluid rhinorrhea: diagnosis and treatment. Current opinion in otolaryngology & head and neck surgery. 2003. 11(1): p. 19-22.
- Crawford, C., N. Kennedy, and W.R. Weir. Cerebrospinal fluid rhinorrhea and Haemophilus influenzae meningitis 37 years after a head injury. The Journal of infection. 1994. 28(1): p. 93-7.
- Ejanel, M.S. and P.M. Foy. Acute traumatic CSF fistulae: the risk of intracranial infection. British journal of neurosurgery. 1990. 4(5): p. 381-5.
- Sampaio, M.H., et al. Predictability of quantification of beta-trace protein for diagnosis of cerebrospinal fluid leak: cutoff determination in nasal fluids with two control groups. American journal of rhinology & allergy. 2009. 23(6): p. 585-90.
- Algin, O., et al. The contribution of 3D-CISS and contrast-enhanced MR cisternography in detecting cerebrospinal fluid leak in patients with rhinorrhea. The British journal of radiology. 2010. 83(987): p. 225-32.
- Shetty, P.G., et al. Evaluation of high-resolution CT and MR cisternography in the diagnosis of cerebrospinal fluid fistula. AJNR. American journal of neuroradiology. 1998. 19(4): p. 633-9.
- Stone, J.A., et al. Evaluation of CSF leaks: high-resolution CT compared with contrast-enhanced CT and radionuclide cisternography. AJNR. American journal of neuroradiology. 1999. 20(4): p. 706-12.
- Jayakumar, P.N., et al. 3D steady-state MR cisternography in CSF rhinorrhea. Acta radiologica. 2001. 42(6): p. 582-4.
- Schlosser, R.J. and W.E. Bolger. Management of multiple spontaneous nasal meningocystocele. The Laryngoscope. 2002. 112(6): p. 980-5.
- Seth, R., et al. The utility of intrathecal fluorescein in cerebrospinal fluid leak repair. Otolaryngology--head and neck surgery : official journal of American Academy of Otolaryngology-Head and Neck Surgery. 2010. 143(5): p. 626-32.
- Lund, V.J., et al. Optimum imaging and diagnosis of cerebrospinal fluid rhinorrhea. The Journal of laryngology and otology. 2000. 114(12): p. 888-92.
- Mostafa, B.E. and A. Khatagi. Combined HRCT and MRI in the detection of CSF rhinorrhea. Skull base : official journal of North American Skull Base Society ... [et al.]. 2004. 14(3): p. 157-62; discussion 162.
- Tabbea, A., et al. The efficacy of computer assisted surgery in the endoscopic management of cerebrospinal fluid rhinorrhea. Otolaryngology--head and neck surgery : official journal of American Academy of Otolaryngology-Head and Neck Surgery. 2005. 133(6): p. 936-43.
- Chiu, A.G., J.N. Palmer, and N. Cohen. Use of image-guided computed tomography-magnetic resonance fusion for complex endoscopic sinus and skull base surgery. The Laryngoscope. 2005. 115(4): p. 753-5.

DISCUSSION

The limitations and morbidity associated with diagnostic imaging studies such as HRCT, MRI, and CT cisternography in detecting CSF leaks has created a need for more accurate and less invasive radiographic imaging modalities.

In our study we evaluate a novel technique of fusing HRCT and MRI imaging for the detection of CSF leaks, as well as its ability to aid in intra-operative localization of skull base defects.

Mostafa et al were the first to describe fusion of HRCT and MRI imaging modalities with reported sensitivity of 89.74%. [1] In our study HRCT and MRI fusion imaging accurately identified and localized the leak in each of the 11 patients diagnosed with CSF leaks on operative nasal endoscopy providing a sensitivity of 100%. We believe one possible contributor to the improved screening ability of this diagnostic study in our series of patient's was that of obtaining 1mm thickness cuts on CT images as opposed to the 3mm slices used in the aforementioned study.

We feel by fusing the two imaging modalities we have created a novel technique were well-defined bony anatomy, CSF fluid, and soft tissue structures (e.g meningoceles, encephaloceles, etc.) can be visualized in an overlapping technique without having to sacrifice for one for the other. With regard to isodense structures as seen on HRCT, the use of fusion imaging also provides self-assurance in delineating nasal mucosa & secretions from that of intracranial soft tissue contents.

CONCLUSIONS

HRCT-MRI fusion is an excellent imaging modality that not only provides accurate identification and localization of CSF leaks but also acts as a great adjunct for intra-operative localization and repair. We believe that this new modality may not only improve surgical confidence but may also have the potential to decrease surgical complication rates. HRCT-MRI Fusion should be incorporated into the diagnostic algorithm in the management of CSF leaks.