A Single-Stage Combined Anterolateral–Posterolateral Approach for Craniovertebral Junction Chordomas: Anatomical Study and Case Illustration.

Verónica de los Santos, MD[1,2]; Gabriel Heemann, MD[1,2]; Arianna Fava, MD[1,2]; Nobuyuki Watanabe, MD[1,2]; Thibault Passeri, MD[1,2]; Sébastien Froelich, MD, PhD[1,2]

[1] Department of Neurosurgery, Hôpital Lariboisière, Paris, France. [2] Laboratory of Experimental Neurosurgery, Department of Neurosurgery, Hôpital Lariboisière, Paris, France

Introduction

- *Craniovertebral junction (CVJ) chordomas* are surgically challenging due to their deep midline bone origin, circumferential extension, and intricate neurovascular relationships, often requiring both wide exposure and craniocervical stabilization.
- *Tumors with both ventral and dorsal extension frequently exceed the limits of a single surgical corridor.* Endoscopic endonasal approaches are generally effective for midline lesions above C2, while posterolateral routes are preferred for lateral extensions above C2 and allow fixation during the same stage. In contrast, the anterolateral approach provides access to CVJ lesions extending inferiorly to the upper cervical spine and to the parapharyngeal space, but usually requires a second stage for stabilization.
- In cases of extensive circumferential extension, no conventional approach provides both adequate anteroposterior and contralateral exposure and stabilization in a single stage. We propose a *combined anterolateral–posterolateral CVJ approach* for these cases, providing circumferential exposure and simultaneous stabilization, with an anatomical description and clinical illustration.

Methods

- Six formalin-fixed, colored latex-injected adult cadaveric heads underwent a standardized right side single-stage combined anterolateral–posterolateral CVJ approach. The dissections were performed microscopically with endoscopic assistance and neuronavigation in the *Laboratory of Experimental Neurosurgery, Hospital Lariboisière, Paris.*
- A detailed description of the approach's stages and the relevant anatomy for each Step is provided. Pre- and post-dissection CT scans were obtained to quantify bone removal and circumferential exposure of the combined approach. To illustrate clinical applicability, we also present a case of a CVJ chordoma successfully resected through this approach.

Results

- A right-sided combined anterolateral–posterolateral CVJ approach was performed in all specimens. The sequential stages of the dissection are illustrated below.

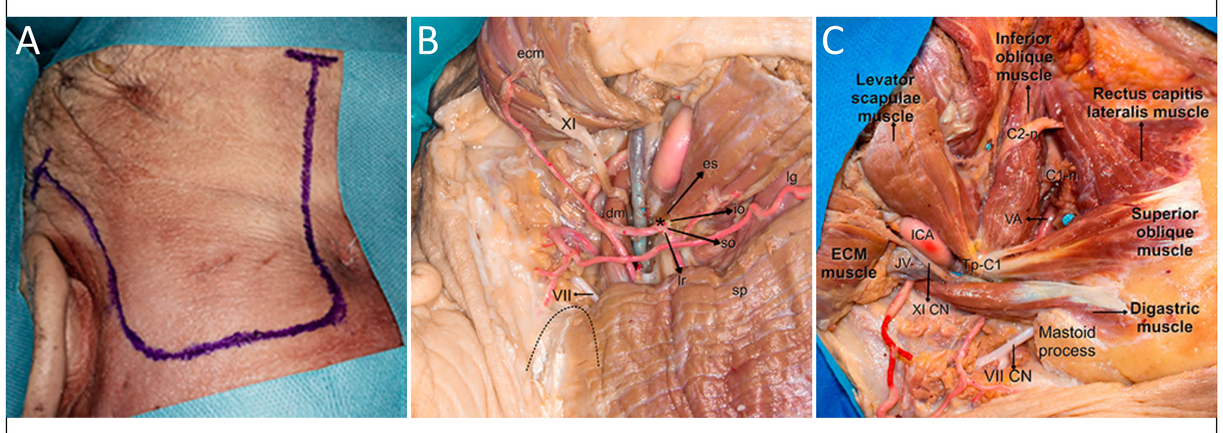

-**Figure 1.** (A) Prone position and anteroinferiorly extended horseshoe-shaped incision. (B–C) Muscular stage. The C1 transverse process (Tp-C1 / black asterisk) served as the integrating landmark to align both corridors and ensure exposure continuity. *ECM, sternocleidomastoid muscle; XI, accessory nerve; VII, facial nerve; ICA, internal carotid artery; JV, jugular vein; VA, vertebral artery; C1-n, C1 nerve; C2-n, C2 nerve; SO, superior oblique muscle; IO, inferior oblique muscle; LR, longus capitis muscle; SP, spinous process; ES, erector spinae muscle; DM, digastric muscle.*

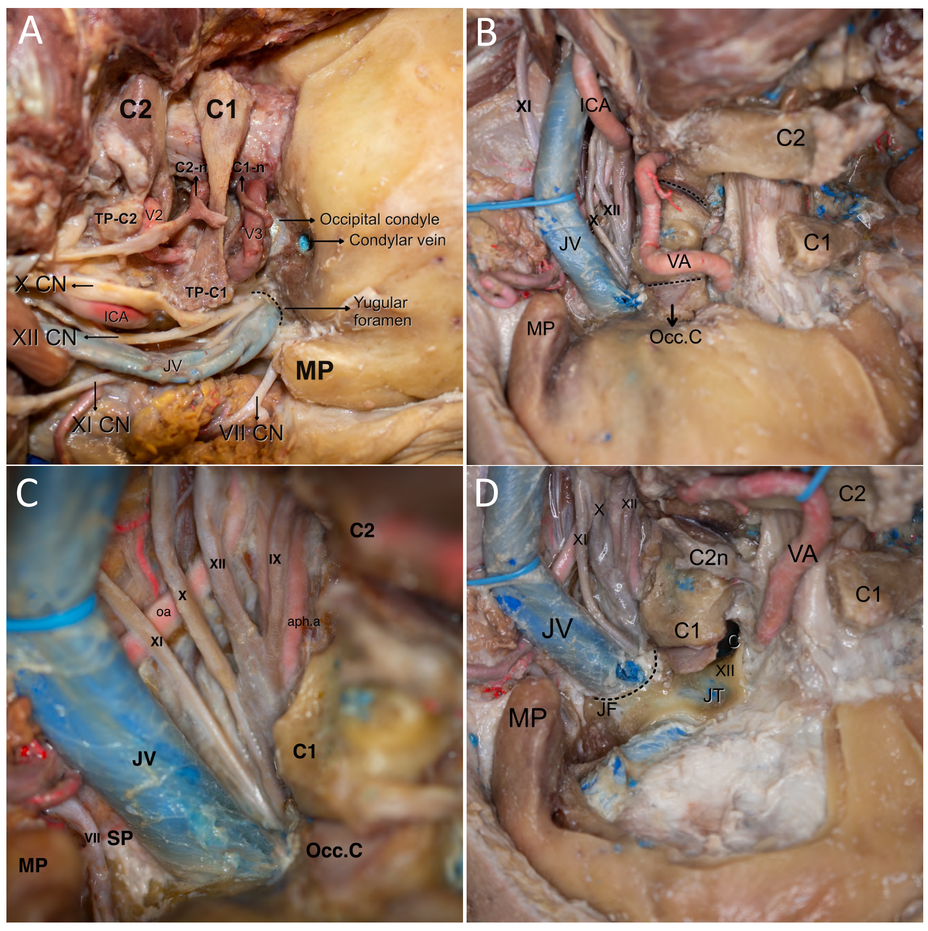

-**Figure 2.** Stepwise bone exposure and neurovascular dissection. (A) Initial osseous exposure (B). Resection of C1's posterior arch and transverse foramina, exposing the vertebral artery (VA-V2-V3). (C) VA transposition and magnified exposure of the lower cranial nerves. (D) Initial occipital condyle drilling. C1, atlas; C2, axis; C1-n, C1 nerve; C2-n, C2 nerve; TP-C1, transverse process of C1; TP-C2, transverse process of C2; ICA, internal carotid artery; JV, jugular vein; Occ.C, occipital condyle; JF, jugular foramen; JT, jugular tubercle; X, vagus nerve; XI, accessory nerve; XII, hypoglossal nerve; IX, glossopharyngeal nerve; VII, facial nerve; SP, spinous process; MP, mastoid process; oa, occipital artery; aph.a, ascending pharyngeal artery.

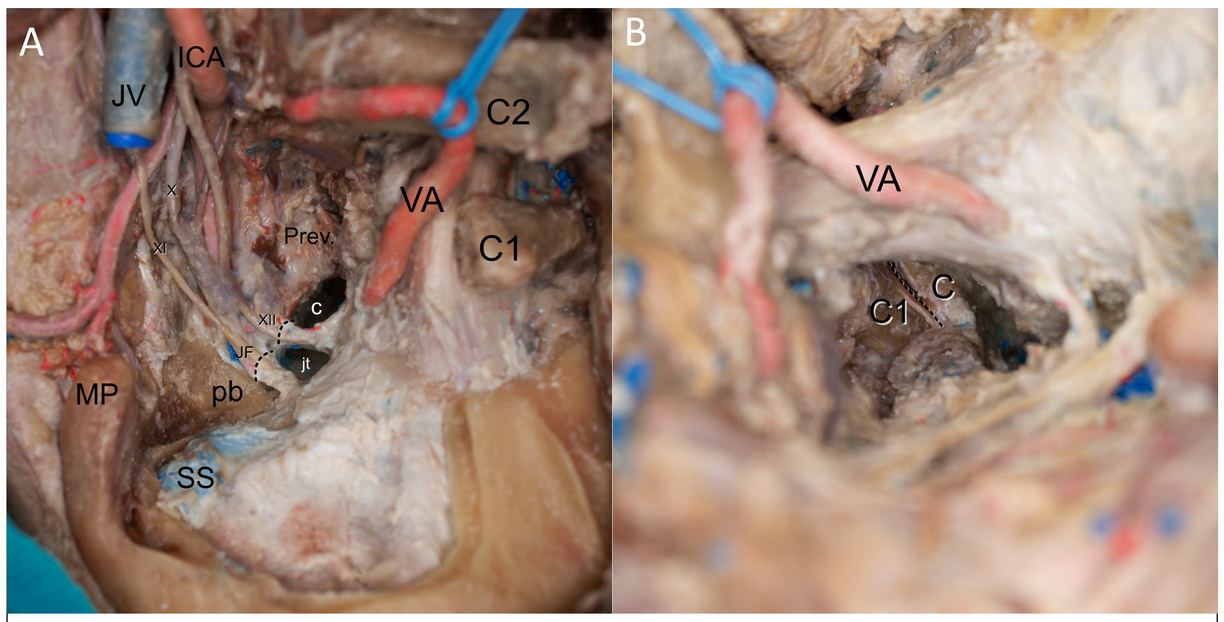

-**Figure 3:** Final surgical exposure after completion of osseous drilling in the combined approach. (A) Posterior view following C1, occipital condyle, and lower clivus drilling. (B) Final posterolateral view demonstrating the extended ventral exposure achieved, including the occipital condyle (C) and the contralateral C1 lateral mass. ICA, internal carotid artery; JV, jugular vein; VA, vertebral artery; C1, atlas; C2, axis; MP, mastoid process; SS, sigmoid sinus; pb, petrous bone; JF, jugular foramen; jt, jugular tubercle; X–XII, lower cranial nerves.

- Post-dissection CT scans were used for quantitative analysis of bone removal and circumferential exposure. Mean circumferential exposure at C1 was 302 ± 8 degrees, corresponding to near-complete circumferential exposure with preservation of part of the lateral mass and transverse foramen. Mean lower clivus bone removal was 72 ± 5%, based on volumetric CT analysis.

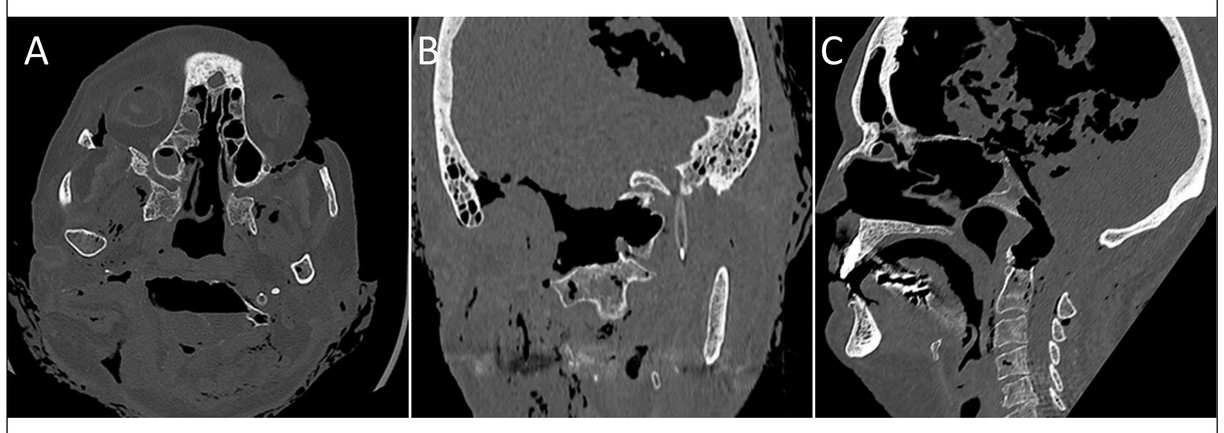

-**Figure 4:** Post-dissection CT scans used for quantitative analysis. Axial (A), coronal (B), and sagittal (C) views demonstrating lower clivus bone removal and circumferential exposure at the level of C1.

- **Clinical Illustration:** A craniovertebral junction chordoma with extensive circumferential extension was resected through the combined anterolateral–posterolateral approach. Complete tumor removal and occipitocervical fixation were achieved in a single operative stage. Postoperative imaging confirmed gross total resection and stable instrumentation.

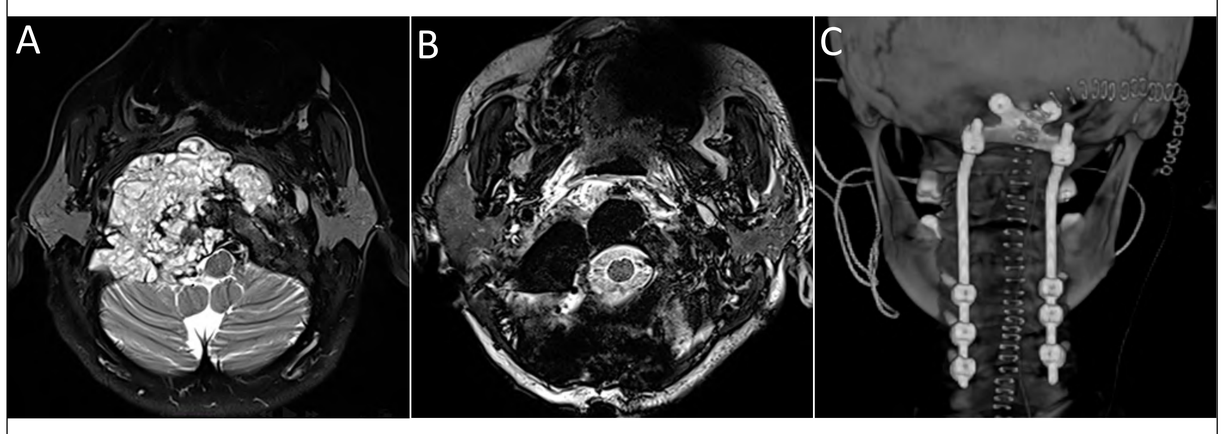

-**Figure 5:** CVJ chordoma. Preoperative T2-weighted MRI (A); postoperative T2-weighted MRI (B); postoperative CT reconstruction showing occipitocervical fixation (C).

Discussion

- The combined anterolateral–posterolateral approach expands the circumferential exposure of the CVJ and represents a single-stage option for CVJ chordomas with both ventral and dorsal extension. By integrating anterior and posterior corridors, this strategy allows wide anteroposterior visualization while preserving the ability to perform stabilization during the same operative setting.
- Using the transverse process of C1 as a central landmark demonstrates the added value of integrating both routes, establishing reproducible reference points that can guide surgical planning and support patient selection. This anatomical framework facilitates corridor alignment and enhances surgical orientation in complex circumferential lesions.

Conclusions

- This anatomical study demonstrates that a single-stage combined anterolateral–posterolateral approach can achieve wide circumferential exposure of the craniovertebral junction while enabling resection and stabilization in the same operative setting.